

See discussions, stats, and author profiles for this publication at: <https://www.researchgate.net/publication/349090002>

INTRANASAL SPLINT REMOVAL AFTER SEPTAL SURGERY OPTIMUM TIMING

Article · February 2021

CITATIONS
0

READS
31

4 authors, including:



Hamada Fadi
Benha University

12 PUBLICATIONS 0 CITATIONS

SEE PROFILE

INTRANASAL SPLINT REMOVAL AFTER SEPTAL SURGERY OPTIMUM TIMING

Mohammed E Hassan, Hamada Fadl Hashem, Alaa M abdelsamei, Ayman Abdelaal Mohamdy

Abstract

Introduction: Insertion of intranasal splints (INSs) after septal surgery with or without turbinate surgery can cause significant pain and discomfort. Up till now there is no evidence about the accepted optimal time for INSs removal.

Aim of work: To investigate the optimal time for intranasal splints removal in patients undergoing septal surgery.

Method: A prospective randomized clinical study was carried out in Benha University Hospital from April 2018 to February 2019. It included 60 patients who underwent septoplasty with or without turbenoplasty. All patients who were splinted by silicone nasal splint bilaterally. Patients were allocated into three groups (A, B and C) according to the time of splint removal (3, 5 and 7 days respectively). The three groups were compared regarding the bleeding, pain, infection, septal hematoma, septal perforation, crustation and adhesions.

Results: Median pain score was significantly higher in-group C than group A (P value = 0.031). Median pain score was significantly higher in-group C than group B (P value = 0.045). Adhesions showed non-statistical significant difference between three groups (P value = 0.766). Crustations showed non-statistical significant difference between three groups (P value = 0.863). Bleeding showed non-statistical significant difference between three groups (P value = 0.863). Infection showed non-statistical significant difference between three groups (P value = 0.766). No septal perforation or hematoma was recorded.

Conclusion: Early removal of INSs significantly affects patient's comfort and decreases pain. However incidence of other postoperative complications increased with short splint duration but it was statistically in significant. So we recommend INSs removal after 5 days as an optimal removal time.

Keywords: Intranasal splints, optimum, timing, splint removal, septal surgery, optimum duration, complications, bleeding, pain, infection, septal hematoma, septal perforation, crustation and adhesion.

Abbreviations: INSs

Introduction

Septoplasty is a common operation performed in Otorhinolaryngology. This operation can be carried out alone or in combination with inferior turbinoplasty, endoscopic sinus surgery and rhinoplasty [1]. Otorhinologists used intranasal splint to for septal support and to avoid postoperative complications [2]. These complications include adhesion, crustations and residual deviation after septal surgery [3]. Different types of splinting materials are reported in literature as silicon rubber splints, Teflon, x-ray film splints and polythene splints. Even splints were made from empty IV fluid bottles and plastic milk bottles [4]. Recently, silicone splints have become more preferable in septum surgery compared to the other materials as it has the advantage of being safely and comfortably retained intranasally longer than other materials. This splint can be remaining intranasal for long duration up to 10 days in some cases [5]. The possibility of leaving the splints intranasally for extended periods helps stabilize the septum in the midline. However, there is nothing in the literature about how long these splints can be retained inside the nasal cavity without increasing the risk of infection, postoperative complications, and patient discomfort [5].

The timing of Intranasal splints removal after surgery is still controversial and nothing in the literature about how long these splints can be retained inside the nasal cavity without increasing the risk of postoperative complications [5].

Aim of the work

To investigate the optimal time for intranasal splints removal in patients undergoing septal surgery.

Patients And Methods

A randomized prospective clinical study of sixty patients attending Benha University hospital outpatient clinic who are candidate for septoplasty with or without turbinoplasty in the period from April 2018 to February 2019. For all patients the surgical indication was nasal obstruction.

Inclusion criteria:

- 1- Patients suffering from nasal obstruction due to septal deviation (all type of deviation) with or without hypertrophied inferior turbinate.
- 2- Patients aged between 18-40 years old.

Exclusion criteria:

- 1- Patients with pervious history of nasal surgery.

- 2- Patients with other intranasal pathologies as nasal polyp or sinusitis.
- 3- Patients in which there was intra operative septal perforation.
- 4- Patients with poor general condition.
- 5- Patients with systemic diseases including diabetes mellitus, renal, hepatic, cardiac and hypertension.

All operative and non-operative procedures were explained in full detail to the patients, who provided an informed consent and accepted to be involved in the study. Also, approval from the ethical committee of ENT department, Benha University was obtained.

Patients were randomly allocated into three groups using closed envelop method.

Operative procedures:

The surgical procedures were performed under general anesthesia. All operations were performed by the same surgeon.

Local hemostasis was achieved by injecting 2 ml of xylocaine and epinephrine 1:200,000 into the caudal septum in the submucoperichondrial plane. Hemitransfixion incision was done, mucoperichondrial flap was elevated, septal incision, elevation of mucoperichondrial flap on the other side and, if needed, the mucoperiosteum was also elevated according to the location of

pathology. After the correction of the bony and cartilage deviation, hemitransfixion incision was sutured with 3-0 absorbable vicryl sutures^[3].

Silicone INSs were inserted into both nasal cavities and fixed by 3-0 absorbable vicryl sutures (**Figure 1**).

Inferior turbenoplasty was done using partial turbinectomy technique which involves removal of posterior portion of the inferior turbinate by direct visualization or with the aid of an endoscope. At the end of the operation, the nose was packed with antimicrobial wet dressing gauze in all cases.

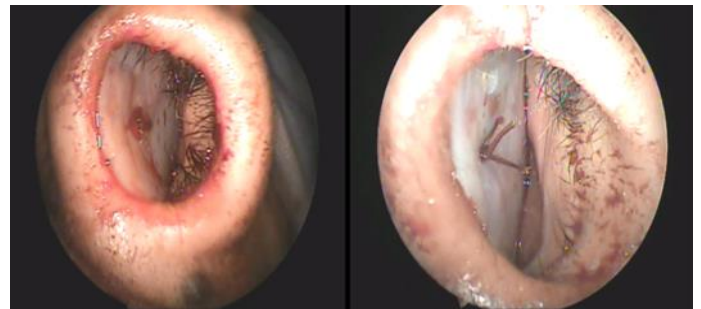


Fig 1: Showing postoperative silicone nasal splint fixation

Postoperative Assessment:

The nasal pack was removed after 48 hours. The patients of all groups were given prophylactic systemic antibiotics (Amoxicillin clavulanic acid) for 5 days after operation & alkaline nasal wash to have nasal douche at home 3-4 times daily. Patients were discharged from the hospital and followed up in outpatient clinic for 4 weeks.

The patients were randomly distributed into 3 groups (A, B, &C) according to splint removal time. Group (A) comprises patients whose nasal splints were removed 3 days after surgery. Postoperative Pain during removal of the splint was evaluated with visual analog scale (VAS) (Figure 2). Any bleeding, infection, septal hematoma, septal perforation, crusting, and synechia formation after splint removal were recorded.

after surgery, group (B) comprises patients whose splints were removed 5 days after the surgery, and group (C) comprises patients whose splints were removed 7 days after the

The postoperative visits were at the time of splint removal, the tenth postoperative day, and the fourth postoperative week. Endoscopic examination was performed to compare rate of postoperative complications.

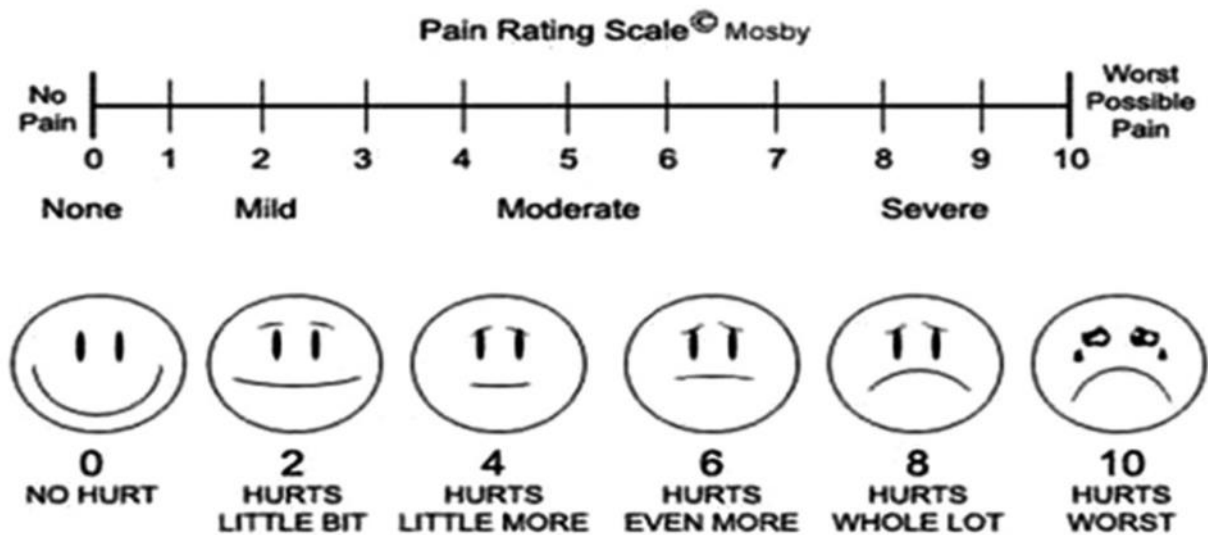


Fig 2: Visual linear analog scale (0–10 numeric pain distress scale) [6]

Data management and statistical analysis were done using SPSS vs.25. Fisher’s exact test was used between groups. Within groups analysis was done using Cochran’s Q test. No pairwise analysis was done due to non-significant comparisons.

Mann Whitney U test was used for comparisons between groups. Within groups comparisons were done using Friedman’s test. **P1** = Overall comparison between three groups, **P2** =Comparisons between group A & group B, **P3**= comparison between group A & group C, **P4**= comparison between group B & group C, **P5**= Overall comparison between 3 days, 10 days & 4 weeks within each group, **P6** = comparison between 3 & 10 days, **P7**= comparison between 3 days

& 4 weeks, **P8=** comparison between 10 days & 4 weeks. All pairwise comparisons were Bonferroni adjusted.

Results

A total of 60 [35(58.33%) male and 25(41.66%) female] patients were included in this study, with age range from 18 to 40 years old and mean follow-up period of 4 weeks (range: 2–6 weeks) (**Table 1**).

Table 1: Demographic characteristics in different study groups

		Group A (n = 20)	Group B (n =20)	Group C (n = 20)	P value
Age (years)	Mean \pm SD	27 \pm 7	27 \pm 7	26 \pm 5	0.88
Gender	Males	11 (55.0)	12 (60.0)	12 (60.0)	0.934
	Females	9 (45.0)	8 (40.0)	8 (40.0)	

These patients were divided into 3 groups according to splint removal time. In the first group (A) intranasal splints were removed 3 days after surgery, in the second group (B) splints were removed 5 days after the surgery and in the third group (C) splints were removed 7 days after the surgery. Each group includes 20 patients.

Regarding the type of procedures performed in all groups, 29 (48.33%) patients underwent septoplasty and 31 (51.66%) patients underwent Septoplasty with inferior turbinoplasty.

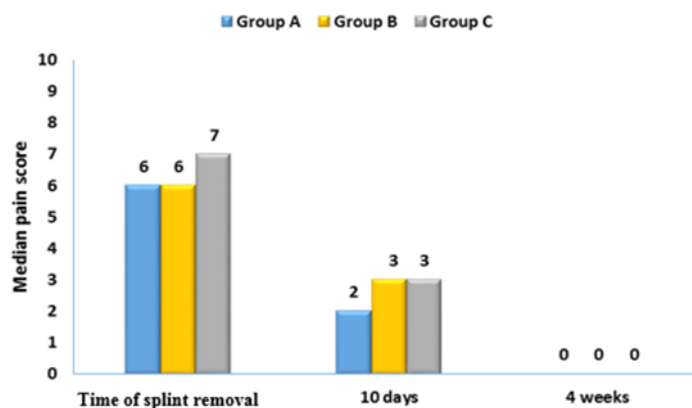
Regarding the type of procedures performed in groups A, [12 (60%) patients underwent septoplasty and 8 (40%) patients underwent Septoplasty with turbinoplasty], In group B, [11 (55%) patients underwent septoplasty and 9 (45%) patients underwent septoplasty with turbinoplasty] and In group C, [10 (50%) patients underwent septoplasty and 10 (50%) patients underwent septoplasty with turbinoplasty].

Regardless to type of surgery pairwise analysis revealed that: Median pain score was significantly higher in group C than group A, (P value = 0.031). Median pain score was significantly higher in group C than group B, (P value = 0.045). There was no significant difference in pain score between group A and group B, (P value = 1.0). At 10 days follow up pain score was significantly higher in group C (3) than group A (2), P value = 0.039. However there were no significant differences in pain score between group A and B & group B and C. P values were 0.533 and 0.766 respectively (**Table 2 & Figure 3**).

Table 2: Pain score in different study groups at different follow up times

	Group A (n =20)		Group B (n = 20)		Group C (n = 20)		P1	P2	P3	P4
	Median	Range	Median	Range	Median	Range				
Pain at time of splint removal	6	(3 - 8)	6	(3 - 8)	7	(4 - 9)	0.016*	1.0	0.031*	0.045*
pain at 10 days	2	(0 - 4)	3	(0 - 5)	3	(1 - 4)	0.045*	0.533	0.039*	0.766
pain at 4 weeks	0	(0 - 1)	0	(0 - 3)	0	(0 - 2)	0.316	-	-	-
P5	<0.001*		<0.001*		<0.001*					
P6	0.004*		0.003*		0.005*					
P7	<0.001*		<0.001*		<0.001*					
P8	0.008*		0.013*		0.005*					

Fig 3: Pain score in different study groups at different follow up times



Complications (regardless to type of operation):

Group A

Adhesions were noticed in two (10%) cases (underwent Septoplasty with turbinoplasty) 4 weeks after surgery. We cut the adhesion under local anesthesia with changing light Vaseline packs daily for a week.

Three (15%) case (underwent Septoplasty with turbinoplasty) had significant bleeding on splint removal that required anterior nasal repacking for 12-24 h.

The rest of the cases in the group showed no bleeding, minor self-limited oozing, or minor bleeding controlled by 1–3 ephedrine packs.

There was three (15%) case of infection occurred (two at time of splint removal and one at 10 day after surgery) diagnosed by congested nasal mucosa with mucopurulent discharge. It was managed by local and systemic decongestant and systemic antibiotics (Amoxicillin clavulanic acid) for 5 days.

Group B

Single unilateral adhesion was noticed in only one (5%) patients in group A (underwent septoplasty with turbenoplasty) by the fourth week after surgery. It managed as mentioned before.

Two (10 %) cases (underwent septoplasty with turbinoplasty) had significant bleeding on splint removal that required anterior nasal repacking for 12–24 h.

There was only one (5%) case of infection occurred at time of splint removal diagnosed and managed as before.

Group c: It showed no bleedings, adhesions or infection.

No septal hematoma or septal perforation was reported in all study groups at different follow up periods.

All groups showed no significant difference regarding incidence of complications (Table 3-6) & (Figure 4-7).

Table 3: Frequency distribution of adhesions in different study groups at different follow up times

	Group A (n = 20)		Group B (n = 20)		Group C (n = 20)		P value
	N	%	N	%	N	%	
Adhesions at time of splint removal	0	0.0	0	0.0	0	0.0	-
Adhesions at 10 days	0	0.0	0	0.0	0	0.0	-
Adhesions at 4 weeks	2	10.0	1	5.0	0	0.0	0.766
P value	0.135		0.368		-		

Table 4: Frequency distribution of bleeding in different study groups at different follow up times

	Group A (n = 20)		Group B (n = 20)		Group C (n = 20)		P value
	N	%	N	%	N	%	
Bleeding at time of splint removal	3	15.0	2	10.0	1	5.0	0.863
Bleeding at 10 days	0	0.0	0	0.0	0	0.0	-
Bleeding at 4 weeks	0	0.0	0	0.0	0	0.0	-
P value	0.05		0.135		0.368		

Table 5: Frequency distribution of infection in different study groups at different follow up times

	Group A (n = 20)		Group B (n = 20)		Group C (n = 20)		P value
	N	%	N	%	N	%	
Infection at time of splint removal	2	10.0	1	5.0	0	0.0	0.766
Infection at 10 days	1	5.0	0	0.0	0	0.0	1
Infection at 4 weeks	0	0.0	0	0.0	0	0.0	-
P value	0.223		0.368		-		

Table 6: Frequency distribution of crustations in different study groups at different follow up times

	Group A (n = 20)		Group B (n = 20)		Group C (n = 20)		P value
	N	%	N	%	N	%	
Crustation at time of splint removal	0	0.0	0	0.0	3	15.0	0.1
Crustation at 10 days	2	10.0	1	5.0	3	15.0	0.863
Crustation at 4 weeks	0	0.0	0	0.0	0	0.0	-
P value	0.135		0.368		0.05		

Fig 4: Frequency of Adhesions in different study groups at different follow up times

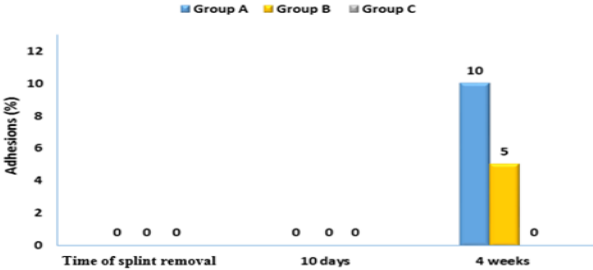


Fig 5: Frequency of bleeding in different study groups at different follow up times

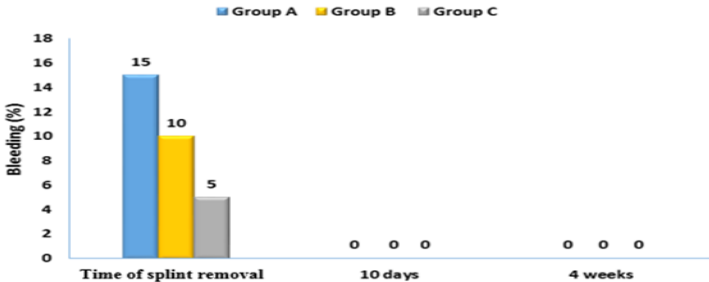


Fig 6: Frequency of infection in different study groups at different follow up times

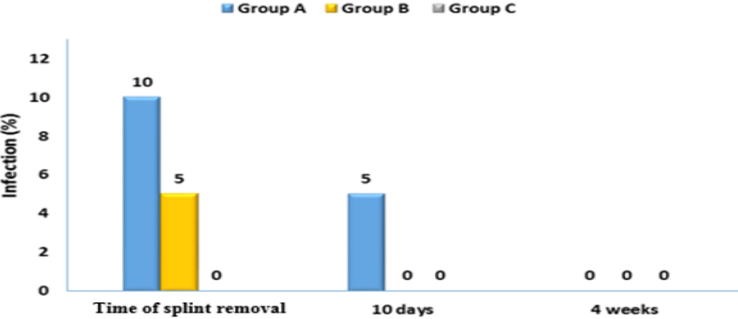
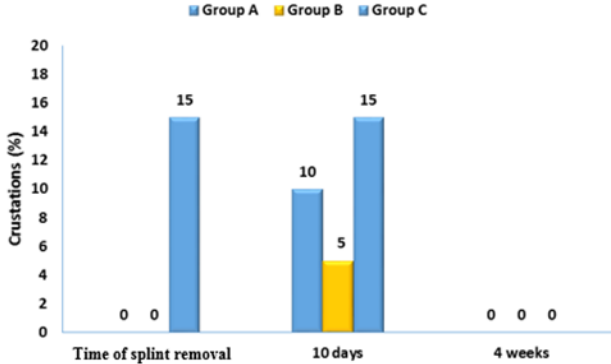


Fig 7: Frequency of crustations in different study groups at different follow up times



Discussion

Intranasal splints (INSs) are widely used after nasal septal surgery for prevention of intranasal adhesions and support of septal position [7]. There are different opinions about optimal time of removal of INSs [8]. There are various opinions in the literature about pain scores and other complications after use of nasal splints.

In this study pain was significantly higher in group C (7 day splint) than in group A (3 days splint) and group B (5 days splint). Also pain was more significant in patients who underwent septoplasty with turbinate surgery than in patients who underwent septoplasty alone.

This result coincides with Aksoy et al., 2011 [1] who reported that with the removal of INSs in 24 hours after surgery the discomfort and the pain would be less without changing the postoperative complication rates.

Other results refuse long splint period. *Campbell et al., 1987* [9] who reported that the splints significantly increased the pain and discomfort from the nasal operations in the early post-operative period. Pain scores were higher in the patients with nasal splints compared to the patients without splints. Also another study by *Malki et al., 1999* [10] reported that one week post-

operatively the patients with splints were experiencing significantly more pain and discomfort than the group without splint.

But these results didn't coincide with *Ozdogan F et al., 2016* [8] who reported there was no significant difference in nasal fullness and pain on the 3rd, 5th, and 7th days.

Our study results showed that adhesions occurred in A and B groups, but didn't occur in C group with no significant effect of time of splint removal on incidence of adhesions. Adhesions mainly happened in patients who underwent combined septoplasty and partial inferior turbinectomy due to presence of two raw surfaces opposite each other but it did not happen in patients who underwent septoplasty alone.

These results coincide with *Ozdogan F et al., 2016* [8] who reported that Nasal synechia was detected in two patients in the 1st group (3 day splint) and in one patient in the 2nd group (5 day splint) at the 8th week, but was not detected in the 3rd group but the percentage of adhesion formation was insignificant between three groups. Also *Aksoy et al., 2011* [1] reported that there is no significant difference in percent of adhesion formation between the removal of INSs in 24 hours and after 5 days of operation.

But these results didn't coincide with *Malki et al., 1999* [10] who reported that nasal splints are not effective in the prevention of nasal adhesions and finally adhesions will occur in splinted and un splinted patients as they compared splinted with un splinted sides while in our study we used splints on both sides.

Bleeding was minimal, only few cases showed massive bleeding in group A and B at time of splint removal that controlled by anterior nasal packing for 12 – 24 h with no significant difference. Bleeding happened especially in patients who underwent septoplasty with inferior turbinoplasty.

This also was reported by *Ozdogan F et al., 2016* [8] who found that Early-period hemorrhage was detected in two patients in the 1st group(3 day splint) and in one patient in the 3rd group(7 day splint), but was not detected in the 2nd group (5 day splint). But there was no significant difference between three groups.

Nasal Crustation is common after any kind of nasal surgery. However, nasal crusting is not mentioned a lot in literature as a complication of nasal surgery as it usually resolves and easily managed by continuous irrigation and nasal wash. In our study, the incidence of crustations was in

significance higher in group C (7 day splint) mainly with turbinate surgery.

Our study showed that infection was insignificant. Infection occurred in the 1st and 2nd groups, but didn't occur in the 3rd group. Only minor infections in the form of vestibulitis and infection of incision site did occur, but no major infection was recorded.

This result coincides with *Ozdogan F et al., 2016* [8] who reported that the incidence of infection in the three groups in which splints were removed after 3, 5, and 7 days was statistically insignificant.

No septal hematoma or septal perforation was recorded in our study. This result not coincides with *OzdoganF et al., 2016* [8] who reported septal hematoma was detected in one patient in the 1st group and was not detected in the other groups. Also, septal perforation was detected in one patient in the 1st group at the 24th week and was not detected in the other groups as more patients were included in this study than our study.

Conclusions and recommendations:

Use of intranasal splints after septal operations is thought to be helpful in preventing adhesions. However, it is associated with pain and discomfort sensation. Our study shows that early removal of INs, group A (after 3 days)

and group B (after 5 days), significantly affects the patient's comfort and decreases pain sensation than group C. In spite of the incidence of complications are increased with short splint duration but statistically in significant.

So we recommend removal of intranasal splints on the 5th day (group B) as an optimal time as it associated with less discomfort, less pain on splint removal than 7th day and also the incidence of complications less than 3 day splinting.

Also we recommend more studies comparing 5 day splinting with less duration and with no splinting. In addition, we recommend doing these studies on larger scales and longer periods of follow-up. In addition, we recommend comparing different splint materials results.

Financial support and sponsorship: Nil.

Conflicts of interest: There are no conflicts of interest.

References

[1] **Aksoy E, Serin GM, Polat S, Kaytaz A.** Removing intranasal splints after septal surgery. *Journal of Craniofacial Surgery.* 2011 May 1; 22(3):1008-9.

[2] **Sarin V, Singh B, Anand V, Gill JS.** Nasal splints after routine nasal surgery: how justified is it. *Pakistan J Otolaryngol.* 2013; 29:22-4.

[3] **Jung YG, Hong JW, Eun YG, Kim MG.** Objective usefulness of thin silastic septal splints after septal surgery. *American Journal of Rhinology & Allergy.* 2011 May; 25(3):182-5.

[4] **Naik SM, Ravishankar B, Shashikumar T, Deekshith T, Sherry C, Pooja N, Sathya P.** Teflon nasal splints in nasal surgeries: advantages over conventional nasal packing. *Online Journal of Otolaryngology.* 2014 Oct 1; 4(4).

[5] **Karatas A, Pehlivanoglu F, Salviz M, Kuvat N, Cebi IT, Dikmen B, Sengoz G.** The effects of the time of intranasal splinting on bacterial colonization, postoperative complications, and patient discomfort after septoplasty operations. *Brazilian Journal of Otorhinolaryngology.* 2016 Dec; 82(6):654-61.

[6] **Zirak N, Esfahanizadeh J, Tashnizi MA, Sepehri Shamloo A, Motahedi B, Soltani G.** Renal function following on-pump versus off-pump CABG. *Iran Heart J* 2014; 14:43-46.

[7] **Tang S, Kacker A.** Should Intranasal Splints Be Used After Nasal Septal Surgery? *The Laryngoscope V C* 2012 the American Laryngological, Rhinological and Otolological Society, Inc., pp. 2012: 1647-1648.

[8] **Ozdogan F, Ozel HE, Esen E, Yuce T, Eyisarac S, Genc S, Selcuk A.** Optimal time for intranasal splint removal after septoplasty: a prospective clinical study. *European Archives of Oto-Rhino-Laryngology*. 2016 Oct 1; 273(10):3203-6.

[9] **Campbell JB, Watson MG, Sheno PM.** The role of intranasal splints in the prevention of post-operation nasal adhesions. *The Journal of Laryngology & Otology*. 1987 Nov; 101(11):1140-3.

[10] **Malki D, Quine SM, Pfleiderer AG.** Nasal splints, revisited. *The Journal of Laryngology & Otology*. 1999 Aug;113(8):725-7.